

# IAS NEWSLETTER



**Dr Sachin Tapasvi**  
President, IAS



**Dr SR Sundararajan**  
General Secretary, IAS  
Editor, IAS Newsletter

Citation for this newsletter: IAS Newsletter-20 March 2023, Vol-3, Issue-3,  
[https://indianarthroscopy.co.in/pdf/IAS\\_Newsletter\\_March\\_2023.pdf](https://indianarthroscopy.co.in/pdf/IAS_Newsletter_March_2023.pdf)

## ARTICLES IN THIS ISSUE

### IAS Academic Corner:

Moderators: Dr Chirag Thonse, Dr Mukesh Laddha

Co-ordinators: Dr Sandeep Biraris, Dr Ramakanth R, Dr Terence

### Expert Talk: Keynotes

Single row, Double row cuff repair- when & how?

Dr PS Jayaprasad(Pg 2)

### Interesting cases:

Arthroscopic Lunate excision in a high-demand individual  
(Pg 3-6)

Arthroscopy In A Pre-School Child: A Case Of Bucket Handle Tear Of  
Medial Meniscus in a 5 Year Old  
(Pg 7- 10 )

# EXPERT TALK

## SINGLE ROW, DOUBLE ROW ROTATOR CUFF REPAIR, WHEN AND HOW?



Dr PS Jayaprasad  
Head of Arthroscopy & Arthroplasty  
Kamineni Hospital, Hyderabad

### HIGHLIGHTS

- Factors impacting outcome:  
Age < 65- Better outcomes  
Smoking-worser outcomes  
Prior corticosteroid injections: Worser outcomes  
Repair construct: ?
- Repair construct-Single row/ Double row?
- Biomechanical studies :  
Higher fixation strength(Double row>Single row)  
Greater footprint coverage(Double row>Single row)
- Clinical studies:  
Not entirely conclusive!  
Larger tears Double-row repair is more favoured than a single row  
Smaller tears single row repair should suffice

# ARTHROSCOPIC LUNATE EXCISION IN A HIGH DEMAND INDIVIDUAL



Dr. B. Bhupesh Karthik, MS(Ortho),  
Consultant SBS Hospital, Hosur

Dr. T. Santhosh, D(Ortho),  
Consultant SBS Hospital, Hosur

## Abstract:

The surgical technique with short-term clinical and radiological outcomes after arthroscopic lunate excision in a high-demand patient are summarised in this case report. We hypothesise that this minimally invasive procedure preserves the dorsal intercarpal and dorsal radiocarpal ligaments and also preserves the movements occurring in the radiocarpal and mid-carpal joints thereby improving the clinical results. Our short-term outcomes show excellent improvement in DASH score at 3 months post-operatively

## Introduction:

Avascular necrosis of lunate is seen increasingly after the covid pandemic. Treatment options include open dorsal lunate excision with or without limited wrist arthrodesis and proximal row carpectomy for Lichtman stage III. Recently, arthroscopic lunate excision is being established as another modality of management for low demand patients. We are reporting our surgical technique, short-term clinical and radiological outcomes following arthroscopic lunate excision in a high demand individual.

## Case Report:

The patient is a 47 year old factory worker with right wrist pain for 20 months. He gives a history of trivial injury to the right wrist. He was initially treated with below elbow cast for a period of 6 weeks after the trivial injury. He continued to have pain which was progressive. On examination he had tenderness over the lunate and a limited range of motion of 15° dorsiflexion and 25° of palmarflexion. Plain x-rays and MRI of the wrist showed collapse of lunate with edema in capitate and minimal scaphoid rotation which confirmed the diagnosis of avascular necrosis of lunate or Kienbock's disease Lichtman stage III A/B(Fig 1).

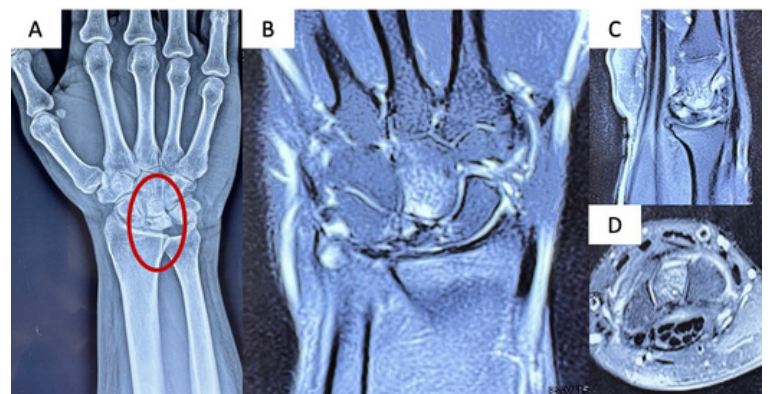

Fig 1: Pre-operative Radiographs & MRI. A: AP radiograph, B, C, D: MRI showing collapse of lunate with edema in capitate

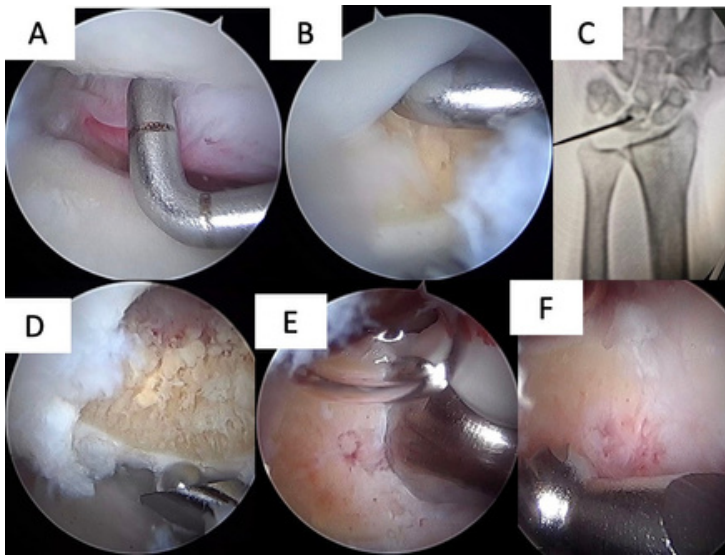


Fig 2: Intraoperative images. A: Probing through the membranous portion of scapholunate junction, B. Probe through the SL junction is able to fracture and enter the weak lunate, C.C-arm image identifying the lunate which is fractured by the probe, D: Burr removing the articular surface of lunate and the bone from scaphoid side towards the lunate, E: Elevators are used to dissect the remnant flake of bone at the LT junction. F: Burr used to remove remnant of bone from the SL junction

## Surgical Technique:

The procedure is performed under regional block with patient in supine position. The upper limb is painted and draped. The wrist is distracted on a traction system with a sterile hand holder. Through standard 3-4 and 6R portals diagnostic arthroscopy is performed. After a diagnostic round, viewing from 3-4 portal, the membranous portion of scapholunate junction is probed from the 6R portal. The fragile bone of the lunate can be fractured using the probe and absence of marrow bleeding from the fractured site can be noted. This maneuver confirms that the lunate is avascular. A c-arm image can be taken to confirm the lunate before starting excision. Using a 2.9mm burr the cartilage and avascular bone of lunate is resected from the scaphoid side towards the triquetral side. After gross excision, the remnants at the scapholunate junction and the lunotriquetral junction are gently mobilised using an elevator and removed using a combination of grasper, shaver and burr (Fig 2). Now the mid carpal ulnar portal is made and the arthroscope is shifted to the mid carpal ulnar portal. The mid carpal radial portal is next made by the outside in technique. Using the shaver and burr the remnants of bone from the distal part of lunate is removed. The proximal articulating surface of capitate is seen well now after complete excision of lunate small bleeding surfaces in the volar capsule are coagulated using the radiofrequency device (Fig 3).

The empty space after lunate excision and adjacent scaphoid and lunate are visualised from midcarpal and radiocarpal portals. Joint lavage is done. Portal closure is done as per surgeon's choice.

## Discussion:

There is limited literature on the outcomes of arthroscopic lunate excision. Reports from Blanco et al in 1985 of open lunate excision through dorsal approach for avascular necrosis of lunate stage III showed satisfactory clinical results<sup>1</sup>. Literature showed only occasional case reports of open lunate excisions until recently Shimizu et al in 2021, published a series of 15 low-demand patients with excellent post-operative pain relief and functional outcomes at 2-year follow-up following arthroscopic lunate excision<sup>2,3,4</sup>. Based on the results by Shimizu et al, we performed arthroscopic lunate excision in a 47-year-old high demand factory worker.

In our case report short term patient related outcome evaluation showed excellent outcomes. DASH score significantly improved to 11.7 at 3 months post-op from 39.2 pre-op. The other treatment options for this condition are lunate excision and limited wrist fusion and proximal row carpectomy. These procedures give good pain relief but the mid carpal and radiocarpal movements are disturbed with these procedures.



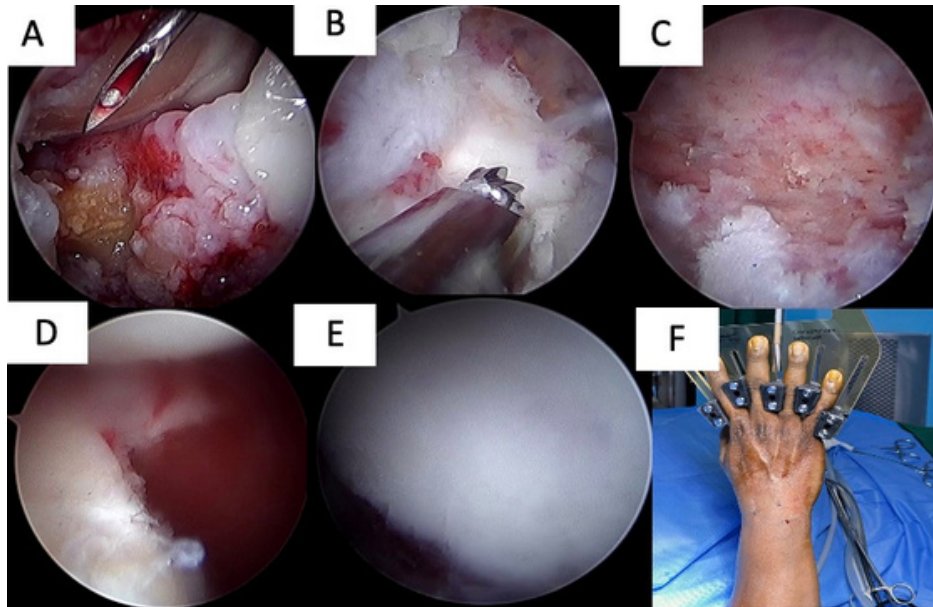


Fig 3: Intraoperative images. A: Mid carpal ulnar portal made by the outside in technique, B. Viewing through the mid carpal ulnar portal remnants of bone is removed from the mid carpal radial portal, C: Volar capsule intact after the excision of lunate, D: Empty area after lunate excision viewed from mid carpal portal, E: The intact triquetrum surface adjacent to empty space after lunate excision, F: Arthroscopic portals at the end of the procedure

With arthroscopic lunate excision, we have the advantage of preserving these articulations and movements.

Open dorsal approach lunate excision disrupts the dorsal intercarpal and dorsal radiocarpal ligaments which destabilises the wrist. Stress on the scaphoid and proximal migration of capitate are unavoidable in any form of lunate excision, but since the dorsal and volar stabilisers of the wrist are left intact with arthroscopic lunate excision we hypothesise that the rate of these events might be slower and will have a lesser impact on clinical outcomes. This is evident in our case report since patient has good clinical outcomes although radiological changes are seen post-operatively (Fig 4).

The advantages of performing lunate excision through arthroscopy rather than open dorsal approach suggests that arthroscopic lunate excision maybe a good procedure in high demand patients also.

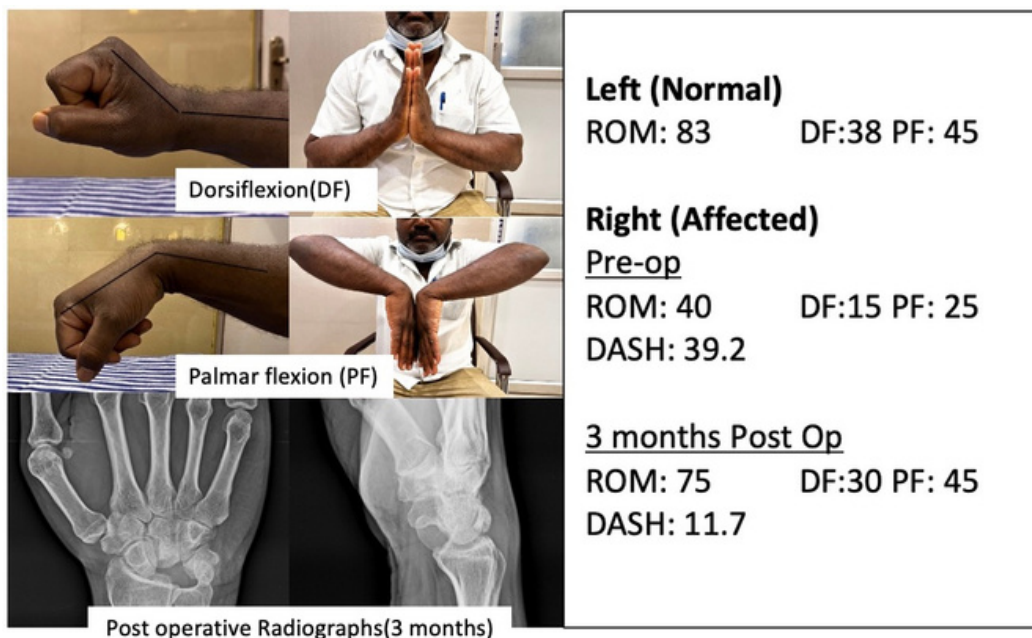


Fig 4: Post-operative clinical and radiological follow-up

## Conclusion:

Arthroscopic Lunate excision may be a good procedure for avascular necrosis of lunate Stage IIIA/B.

Short-term results are satisfactory in this high-demand patient. Long-term follow-up and a series of cases are required for better evidence.

## References:

1. Blanco RH. Excision of the lunate in Kienböck's disease: Long-term results. *J Hand Surg Am* 1985;10:1008-1013.
2. Wheatley MJ, Finical SJ. A 32-year follow-up of lunate excision for Kienbock's disease: A case report and a review of results from excision and other treatment methods. *Ann Plast Surg* 1996;37:322-325.
3. Rajappa S, Kumar MM. Aneurysmal bone cyst of lunate treated by excision without intercarpal fusion: a case report. *Journal of Hand Surgery (European Volume)*. 2013;38(9):1007-1008.
4. Shimizu T, Omokawa S, Kawamura K, Nakanishi Y, Onishi T, Nagashima M, Hasegawa H, Kurata S, Tanaka Y. Arthroscopic Lunate Excision Provides Excellent Outcomes for Low-Demand Patients with Advanced Kienböck's Disease. *Arthrosc Sports Med Rehabil*. 2021 Aug 28;3(5):e1387-e1394. doi: 10.1016/j.asmr.2021.06.007. PMID: 34712976; PMCID: PMC8527252.

## ARTHROSCOPY IN A PRE-SCHOOL CHILD: A CASE OF BUCKET HANDLE TEAR OF MEDIAL MENISCUS IN A 5 YEAR OLD



Dr Mohammad Maaz,  
Dr Santosh Sahanand,  
Dr David V Rajan.

Department Of Arthroscopy &  
Sports Medicine  
Ortho-One Orthopaedic  
Speciality Centre, Coimbatore,  
Tamil Nadu, India

### Abstract:

Meniscus injuries are amongst common injuries with or without Anterior Cruciate Ligament(ACL) injuries in adults but are rare in paediatric patients, we report A case of bucket handle tear of medial meniscus in a 5 Year old, its challenges in diagnosing, management options available and which one we followed, what are the precautions we take before management, what would be the post op protocol of the same and also review the literature.

### Introduction:

Bucket handle tear of meniscus is longitudinal tear with fragment locked in the intercondylar notch. The first meniscus repair was performed by Annadale in 1885[1], subsequently there were no reports of the same in paediatric patients until 1953 when Volk & Smith[2] reported a case a bucket handle tear of medial meniscus in a 5 year old and some years later in 1970 Saddawi & Hoffman[3] reported a case of meniscus tear in a 4 Year both treated with meniscectomy.

Though there is no clear data available about the incidence of paediatric meniscus tears in literature there have been certain sporadic reports of the same since then.

Various treatments options have been defined but not standardised Bloome et al[4] reported 2 cases managed by arthroscopic inside-out repair, Kramer et al[5] reported 280 bucket handle tears in paediatric population treated with both repair and partial meniscectomy, among repair patients 47% treated with all-inside repair, 47% with hybrid repair, 6% with inside out with use of suture material viz., ethibond, fibrewire & absorbable PDS With the advent of importance of salvage of meniscus on long term adverse effects on knee, meniscus repair is warranted, so the Paediatric meniscus repair, and we report a case of one such rare patient.

### Case Report:

The patient is a 5-Year-old child with history of fall from a wall while playing around it, and a part of wall fell off his left lower limb, He was presumably pulled out of it & consulted an orthopaedician. Child complained of locking , pain and restricted ROM Of the knee.

Radiological evaluation by Xray was done which suggested no bony injury or physeal injury & diagnosed it to be soft tissue injury of knee & treated conservatively with an immobiliser, analgesics and anti-inflammatory medications.

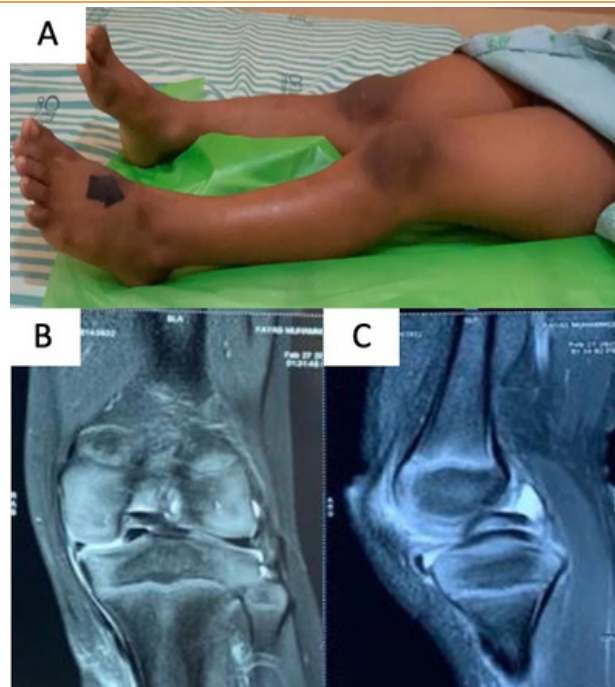


Fig 1: Preoperative images. A: Attitude of 20-degree flexion( not fixed), B, C: Repeat MRI showing unreduced bucket handle tear of the medial meniscus

Parents were concerned due to refractory pain and locking, he was reviewed and MRI was done(Fig 1) which reported a bucket handle tear of the medial meniscus.

Though active extension was not possible, passive extension is possible fully to 0 deg (fig 1), medial joint line tenderness was present, McMurray's test positive for medial meniscus and negative for Lateral meniscus, Lachman's test negative with hard end point, pivot shift test was negative,

As full knee extension was possible, we were of the opinion that the bucket handle component would have reduced from the intercondylar notch into its anatomic place and a review MR was taken. A new MRI (fig1) reported an unreduced bucket handle tear component still in the notch which did not corroborate clinically as full passive knee extension was possible.

He was advised of arthroscopy and medial meniscus repair.

### Surgical Technique:

Diagnostic arthroscopy revealed a bucket handle tear of the medial meniscus(fig 2), a 4mm 30 Deg scope was suitable, inside-out repair of meniscus was planned, the tear was reduced and assessed. Tear was in the RR Zone, extending from middle 3rd to posterior 3rd (fig 2).

We choose to use fibre wire as suture material. Left middle 3rd inside out needle was used for middle 3rd tear, placed 1 suture on superior surface and another on inferior surface. Meniscus left posterior 3rd inside out needle is used for posterior part repair- one each on superior and inferior surface, (fig 2). Repair was confirmed to be stable. Sutures were passed taking care not to entrap the saphenous nerve & artery. A separate small incision is made on the medial part of the knee and these sutures were tied over the capsule. We prefer to use modified Western knots for knot tying in our centre.

### Post-op Protocol:

Though we would have advised 4 week partial weight bearing and then progress to full weight bearing with ROM to achieve 90 Deg in 3 weeks, owing to the active nature of child, we preferred to keep the child Non-weight bearing for 4 weeks and ROM to achieve as mentioned above.

### Follow up:

At 3 months follow-up patient was fully bearing weight with full ROM & occasional pain. Child started playing at 8 months reaching up to pre-injury levels with no pain & no joint line tenderness. At 1 year follow-up the child was playing comfortably with his peers.



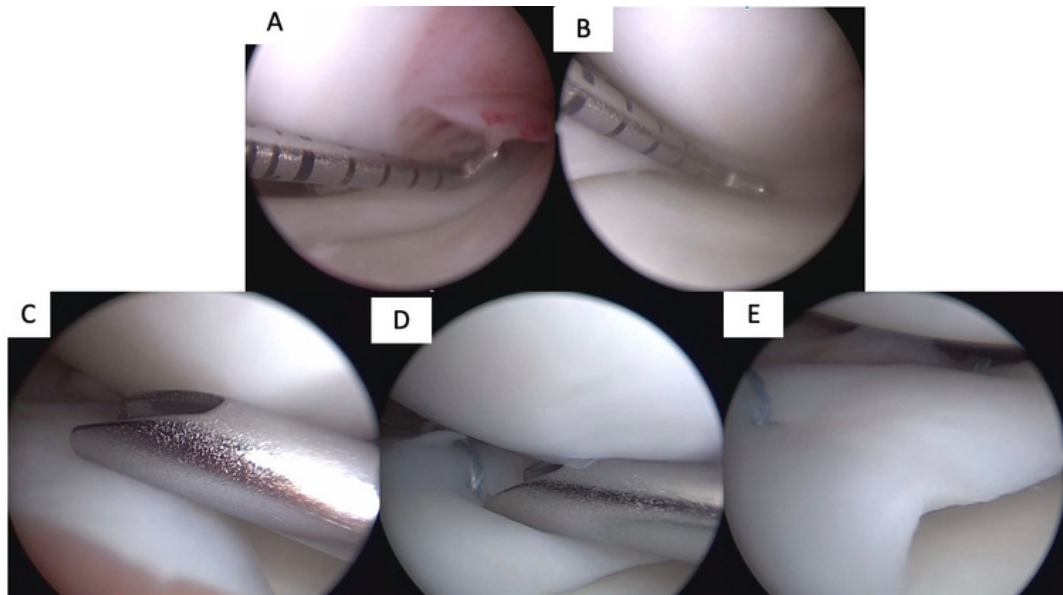


Fig 2: Arthroscopy images. A,B: Bucket handle tear of medial meniscus, C,D,E: Inside out repair

## Discussion:

This is a rare scenario in which the clinician/general orthopaedician would in his/her differential diagnosis suspect at the last with regards to history and nature of the injury. We would have suspected it to be a PCL injury/Bony injury/Physal injury, and according to Examination it would be a discoid lateral meniscus tear / ACL Tibial avulsion. A Positive medial joint line tenderness and mcmurrys test for medial meniscus pointed us towards medial meniscus pathology, which was confirmed with an MRI as a bucket handle tear of the medial meniscus.

A conservative management option would have been advised if a review MRI showed a reduced meniscus from the notch to its anatomical position, due to higher vascularity of meniscus in this age group as reported Clarke et al[7].

Canton et al[6] concluded that meniscectomy should only be considered for irreparable tears and it is always recommended to salvage the meniscus, They also suggested that due to presentation at unusual age if missed or presented late repair should always be considered owing to higher chances of healing at this age as reported by Clarke et al[7].

Though literature is lacking we, found that paediatric cartilage is delicate and more liable to get injured with intra-op manipulation of instruments. We were able to use 4mm scope nevertheless we had 2.7mm scope standby, Kramer et al[5] in his review in 280 BHT mentioned that 2.7mm scope was used. We used a smaller 2mm probe. Unlike adult medial meniscus repair where 4 to 5 sutures on superior and inferior surfaces each are placed, we placed 2 each on superior and inferior surfaces which were sufficient to stabilise this small meniscus. Literature mentions the use of various suture materials viz., PDS, Ethibond, and fibre wire[5] though no studies are available to suggest the advantage of one above the other. We used a fibrewire to provide enhanced stability for meniscus as child is very active but at the cost of increased stiffness. It's worth mentioning that Bloome et al[4], Kramer et al[5], Canton[6] reported that the majority of their cases were managed with all inside repair which is more expensive and requires more expertise but Inside out repair is also a favourable option which is also economical.

## Conclusion:

Common differential diagnosis are always common, but clinician should have a high level of suspicion when medial joint line tenderness and McMurrays test is positive for medial meniscus.

Arthroscopic Inside out repair is a very good option, economical and comes with favourable clinical outcome.

## References:

1. Meniscal tears: Current understanding, diagnosis, and management. Bhan K. Cureus. 2020;12:0.
2. Bucket-handle tear of the medial meniscus in a five-year old boy. H Volk & FM Smith. J Bone Joint Surg Am. 1953 Jan;35-A(1):234-6.
3. Tear of the attachment of a normal medial meniscus of the knee in a four-year-old-child. A case report. ND Saddawi & BK Hoffman. J Bone Joint Surg Am. 1970 Jun;52(4):809-11.
4. Meniscal Repair in Very Young Children. A Case Report. David M. Bloome, Field T. Blevins, George A. Paletta, Jr, Joseph K. Newcomer, Bourke Cashmore and Ronald Turker. Arthroscopy: The Journal of Arthroscopic and Related Surgery, Vol 16, No 5 (July-August), 2000: pp 545-549
5. Outcomes After the Operative Treatment of Bucket-Handle Meniscal Tears in Children and Adolescents. Dennis E. Kramer, Leslie A. Kalish, Daniel J. Martin, Yi-Meng Yen, Mininder S. Kocher, Lyle J. Micheli, and Benton E. Heyworth. The Orthopaedic Journal of Sports Medicine. 2019 10.1177/2325967118820305
6. Bucket-handle meniscal tears in children under the age of 10: a literature review. Gianluca Canton, Guido Maritan, Francesco Impellizzeri, Cristina Formentin and Luigi Murena. Acta Biomed. 2021; 92(Suppl 3): e2021020.
7. Development of the menisci of the human knee joint. Morphological changes and their potential role in childhood meniscal injury. CR Clarke & JA Ogden J Bone Joint Surg Am? 1983 Apr;65(4):538-47.